

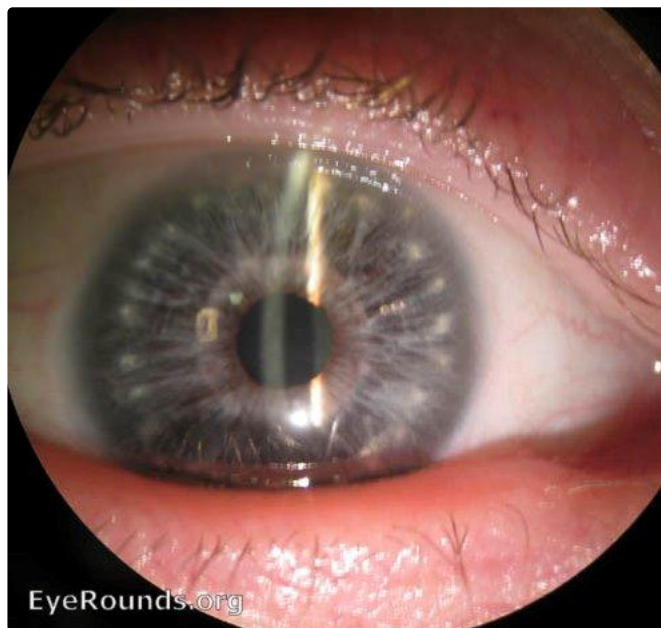
## Down's Syndrome with Brushfield's spots on the iris

Category(ies): [Glaucoma](#), [Iris](#)

Contributor: [Andrew Doan, MD, PhD](#)



Frequently seen in Down's syndrome patients, but can also be seen infrequently in children unaffected by Down's syndrome.



[Enlarge](#) [Download](#)

### Image Permissions:



Ophthalmic Atlas Images by [EyeRounds.org](#), [The University of Iowa](#) are licensed under a [Creative Commons Attribution-NonCommercial-NoDerivs 3.0 Unported License](#).

University of Iowa  
Roy J. and Lucille A. Carver College  
of Medicine  
Department of Ophthalmology and  
Visual Sciences  
200 Hawkins Drive  
Iowa City, IA 52242

[Support Us](#)

Copyright © 2019 The University of  
Iowa. All Rights Reserved  
[Report an issue with this page](#)  
[Web Privacy Policy](#) |  
[Nondiscrimination Statement](#)

[Cataract Surgery for Greenhorns](#)  
[EyeTransillumination](#)  
[Gonioscopy.org](#)  
[Iowa Glaucoma Curriculum](#)  
[Iowa Wet Lab](#)  
[Patient Information](#)  
[Stone Rounds](#)  
[The Best Hits Bookshelf](#)

## Media

Follow



Receive notification of new cases,  
[sign up here](#)  
[Contact Us](#)  
[Submit a Suggestion](#)